

**DATE** **PRESENTING CLINICAL SIGNS**  
8-18-21 History of persistent cough

**INTERPRETED BY** **CYTOLOGY SUBMISSION**  
L.D. McGill, DVM, Ph.D, DACVP FNA of thoracic mass

**PATIENT** **OBSERVATIONS**  
Sadie Miles Lung mass: Submitted are 3 excellent videos of moderate to excellent collections of cells from the lung mass in Sadie. Two of the videos include large numbers of inflammatory cells that are neutrophils, macrophages and necrotic debris. One of the videos has collections of cells that are packeted. These cells have characteristics of epithelial cells from the lung tissue. These epithelial cells are likely derived from pulmonary tissue. They demonstrate slight anisokaryosis.

**SPECIES** **INTERPRETATION OF THE FINDINGS & FURTHER RECOMMENDATIONS**  
Canine Lung mass - Suggestive of pulmonary carcinoma with secondary pyogranulomatous inflammation and necrosis

**BREED** **COMMENTS**  
Golden Retriever There are packets of cells in one of the videos that suggest the likelihood of a pulmonary carcinoma. There is extensive inflammation in and around the proliferative tissue. This inflammation is pyogranulomatous. It's very prominent in most of the videos. Due to the apparent carcinoma cells, an unfavorable prognosis is expected. A follow-up biopsy either by exploratory or punch biopsy will be required to confirm the diagnosis.

**SEX**  
Male Neutered

**AGE** **The information and recommendations provided are based on the images presented by the referring veterinarian. No evaluation can be communicated regarding pathology that was not visible in the image/video clips provided.**  
14 years

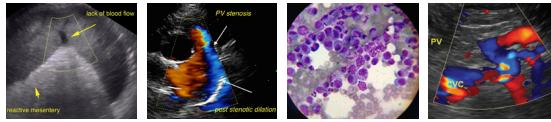
**WEIGHT** Thank you for this referral. If the clinical or image interpretation does not parallel your findings or if I can be of any further assistance please contact me.

49.8#

**HOSPITAL NAME** **L.D. McGill, DVM, Ph.D., DACVP**  
Santa Clara Animal Hospital 8288 Top of the World Drive  
Cottonwood Heights, UT 84121  
ldmcgill.vetpath@gmail.com  
cell: 801-865-1220

**REFERRING VET**  
Dr. Zulaf

**INVOICE NUMBER**  
80287



**DATE**

8-18-21

**INTERPRETED BY**

L.D. McGill, DVM,  
Ph.D, DACVP

**PATIENT**

Sadie Miles

**SPECIES**

Canine

**BREED**

Golden Retriever

**SEX**

Male Neutered

**AGE**

14 years

**WEIGHT**

49.8#

**HOSPITAL NAME**

Santa Clara Animal  
Hospital

**REFERRING VET**

Dr. Zulaf

**INVOICE NUMBER**

80287

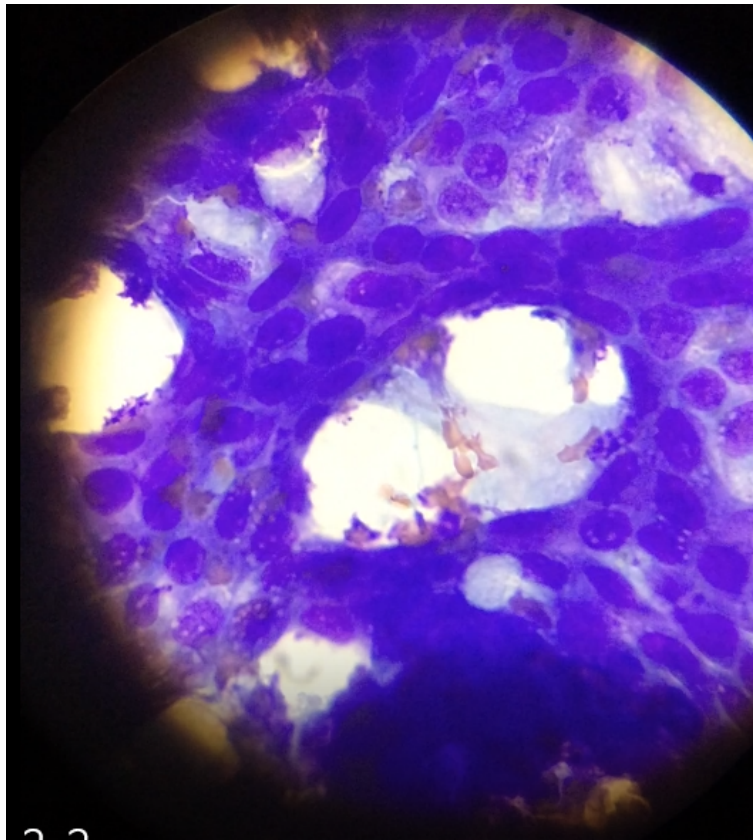


Image shows cells that appear to be carcinoma cells collected from the lung in Sadie. Maybe a collection of mucus in the center.